

Nd:YAG 1064 nm laser in the treatment of facial and leg telangiectasias

A Major,‡ B Brazzini,†* P Campolmi,† P Bonan,† L Mavilia,† I Ghersetich,† J Hercogova,§ T Lottit

†Department of Dermatology, University of Florence, Italy; ‡Private practice, Verona, Italy; §Department of Dermatology and Venereology, Charles

University, 2nd Medical School, Prague, Czech Republic. *Corresponding author, Department of Dermatology, Via degli Alfani 37, 50121 Florence, Italy,

fax +39 0552758329; E-mail: tlotti@unifi.it

ABSTRACT

Background Facial and leg telangiectasias are a frequent cosmetic concern for both females and males with various skin types and ages. To date the different treatments for these problems, in particular leg telangiectasias, have frequently failed or led to negative side-effects.

Objective This study examines the clinical effects and safety of applications with a 1064-nm Nd:YAG laser system (SmartEpil II, DEKA M.e.l.a., Florence, Italy) to treat vessels on the face and legs.

Materials and methods Twenty-five subjects with facial telangiectasias underwent one treatment at 100 J/cm², 10 ms and 2 Hz repetition rate. Thirty-two subjects with leg telangiectasias, measuring 0.1–3 mm in diameter, were treated at 125–200 J/cm², 10–30 ms and 2 Hz repetition rate. Subjects in this group underwent one to five treatment sessions at 8 week intervals.

Results All subjects showed visible improvement, with 95–100% clearing of the face telangiectasias after only one treatment, and 50–100% clearing of the lower extremity vessels after three to five treatments. Transitory hypopigmentation was seen in two cases subjected to leg vessel treatment.

Conclusions Treatment of facial and leg telangiectasias using a true long pulse 1064 nm Nd:YAG laser is an effective and safe method. The relative lack of discomfort combined with a high degree of individual satisfaction should play a part in the fairly high level of acceptance of this new form of therapy for the treatment of leg and face telangiectasias.

Key words: face telangiectasias, laser, leg telangiectasias, Nd:YAG 1064 nm

Received: 20 November 2000, accepted 25 July 2001

Introduction

Telangiectatic vessels on the face and legs are a common cosmetic problem. Face telangiectasias are superficial ectatic vessels of small diameter and thus require treatment that provides a high degree of subject satisfaction and limited side-effects, for example using various laser devices, such as the flashlamp pulsed dye laser 585 and 595 nm,¹ the frequency doubled Nd:YAG 532 nm^{1–3} and intense pulsed light sources.⁴

Leg telangiectasias are more difficult to treat because the lesions are deeper, located at different depths, larger than those of facial telangiectasias, which are all located approximately at the same distance from the epidermis and they present different flow characteristics and a different structure.

The first study on the selective use of a 1064-nm laser on leg telangiectasias and reticular veins was reported by Weiss and Weiss in 1999.⁵ Previous applications of this laser were limited to deep laser coagulation of tissue, large haemangiomas and vascular malformations without considering selective targeting. These investigators demonstrate that the 1064 nm wavelength is much more effective in the treatment of 0.5–3.0 mm dilated leg vessels than that of the shorter wavelength lasers used previously. They also report the occurrence of hyperpigmentation in 42% of their subjects (a percentage similar to that of post-sclerotherapy), but this disappeared in 72% of the cases after 3 months. A recent study⁶ confirms the efficacy of 1064 nm Nd:YAG laser in clearing dilated leg veins, with clearing of 75–100% in eight of 13 subjects and the occurrence of hyperpigmentation in only 23% (three of 13 subjects).

A new device operating on 1064 nm wavelength (SmartEpil II, DEKA M.e.l.a., Florence, Italy) allows treatment of leg telangiectasias using an energy density emission ranging from 100 to 200 J/cm² using a 2.5-mm spot and a pulse width of 10–30 ms.

The present study examined the clinical effects of treatment of leg and face telangiectasias using a 1064-nm Nd:YAG laser system (SmartEpil II, DEKA M.e.l.a.). The study was carried out in the Department of Dermatology, University of Florence, Italy, in the Department of Dermatology of Charles University (Motol), Prague, Czech Republic and in private practice, Verona, Italy.

Materials and methods

In group 1, 25 subjects (15 females and 10 males), skin types 2 and 3, aged between 22 and 54 years, were enrolled and underwent laser treatment for the removal of face telangiectasias. In group 2, 32 subjects (29 females and three males), skin types 2 and 3, aged between 24 and 58 years, were enrolled and underwent laser treatment for the removal of leg telangiectasias. Exclusion criteria included inflammatory disorders of cutaneous circulation, hypercoagulability, large tortuous veins, pregnancy or lactation, systemic diseases, systemic drugs, photosensitivity, history of poor healing or

keloid formation. Vessel number counts, photography and videomicroscopy were performed.

The SmartEpil II, high-energy long-pulse infrared (HELP-I) was used to treat both groups. The unit is a 1064-nm Nd:YAG true long-pulsing laser with pulse widths up to 30 ms and spot sizes from 2.5 to 7 mm. With the 2.5 mm spot the laser can provide fluences up to 200 J/cm². During the treatments the skin was effectively protected by a supply of chilled forced air supplied by an external device (Smartcryo, DEKA M.e.l.a.) that is a component of this laser equipment together with an optical scanner for hair removal. Thus, excellent pre-operative, intra-operative and postoperative skin cooling was achieved together with a constant perfect view of the operative field. Twenty-five subjects in group 1 were treated at 100 J/cm², 10 ms and 2 Hz repetition rate. All the group 1 subjects received only one treatment (Table 1). Group 2 patients were treated at 125–200 J/cm², 10–30 ms and 2 Hz repetition rate; they underwent one to five treatment sessions at 8-week intervals (Table 2). The forced air was applied to the skin through a hose and kept running on each treated area before during and after laser emissions.

No special care was required after the procedure, but all subjects were advised to apply an antibiotic cream in case of crusting, to avoid direct sun exposure and to apply a total sunblock before going outdoors. All subjects were examined 8 weeks after the last laser session to evaluate the necessity of an additional treatment.

Patient no.	Skin type	Age	Maximum diameter (mm)	J/cm ²	ms	No. of treatment sessions	% clearing grade at 1–2 weeks	Adverse effects
1	2	34	0.2	100	10	1	100	–
2	2	45	0.4	100	10	1	100	–
3	2	30	0.4	100	10	1	100	–
4	3	25	0.4	100	10	1	95	–
5	2	46	0.6	100	10	1	100	–
6	3	34	0.2	70	10	1	100	–
7	3	32	0.4	100	10	1	100	–
8	3	29	0.2	70	10	1	100	–
9	2	28	0.6	100	10	1	95	–
10	2	32	0.4	100	10	1	100	–
11	3	44	0.8	100	10	1	100	–
12	2	26	0.4	100	10	1	100	–
13	3	54	0.6	100	10	1	100	–
14	2	27	0.4	100	10	1	100	–
15	2	32	0.4	100	10	1	95	–
16	3	38	0.2	70	10	1	100	–
17	2	45	0.4	100	10	1	100	–
18	3	32	0.8	100	10	1	95	–
19	3	51	1.0	100	10	1	100	–
20	2	22	0.2	70	10	1	100	–
21	2	30	0.2	100	10	1	100	–
22	2	23	0.2	100	10	1	100	–
23	2	52	0.3	100	10	1	100	TH
24	2	40	0.2	100	10	1	100	TH
25	3	35	0.1	100	10	1	100	–

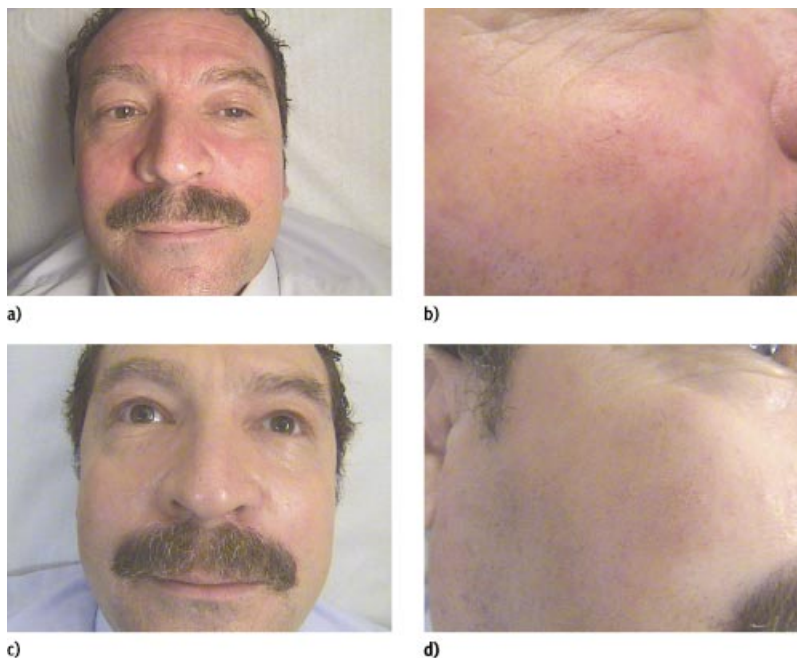
TH, transient hyperpigmentation.

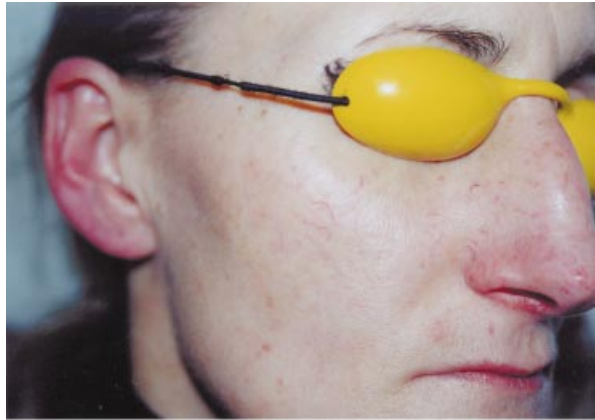
Table 1 Clinical effects of 1064 nm Nd:YAG laser on face telangiectasias

Table 2 Clinical effects of 1064 nm Nd:YAG laser on leg telangiectasias

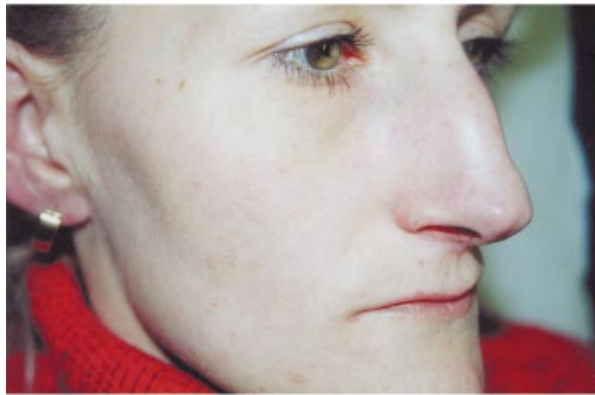Patient no.	Skin type	Age	Maximum diameter (mm)	J/cm ²	ms	No. of treatment sessions	% clearing grade at x weeks	Adverse effects
1	2	34	1.5	200	30	3	50-75	-
2	3	32	1.8	175	20	3	75-100	-
3	3	45	2.5	200	20	5	75-100	-
4	2	28	0.4	125-150	10	1	75-100	-
5	2	30	0.8	175	30	2	75-100	-
6	2	38	1.0	200	30	3	50-75	-
7	3	40	0.8	175	20	1	75-100	-
8	2	34	1.2	200	20	3	25-50	DH
9	2	36	0.8	175	30	1	75-100	-
10	3	44	1.0	150-175	20	3	75-100	-
11	3	48	2.0	200	20	3	50-75	-
12	3	32	0.4	125	10	2	75-100	-
13	2	54	2.8	200	30	4	50-75	-
14	2	41	1.0	200	20	3	75-100	-
15	2	50	1.2	200	30	3	25-50	DH
16	2	29	0.6	125-150	20	2	50-75	-
17	2	33	0.8	175	30	2	50-75	-
18	3	58	2.8	175-200	30	3	50-75	-
19	2	39	1.4	175	30	2	75-100	-
20	3	36	1.0	175	20	3	75-100	-
21	3	42	1.0	150-175	20	3	50-75	-
22	2	28	0.4	150	30	2	75-100	-
23	3	51	1.8	150	20	3	75-100	-
24	2	40	1.0	175	30	3	< 25	-
25	3	56	2.0	200	30	4	50-75	-
26	3	38	1.2	175	20	3	75-100	-
27	2	34	0.8	200	30	3	75	-
28	2	24	0.3	150	10	1	75-100	-
29	3	36	0.5	150	20	2	50-75	-
30	2	29	1.6	175	30	2	75-100	-
31	2	47	1.0	175	20	3	75-100	-
32	3	58	1.2	175	20	3	75-100	-

DH, dotted hypopigmentation.

**fig. 1** Facial telangiectasias: (a, b) before treatment, and (c, d) after one treatment session with Nd:YAG 1064 nm laser.



a)



b)

fig. 2 Facial telangiectasias: (a) before treatment; (b) 30 days after one treatment session with Nd:YAG 1064 nm laser.

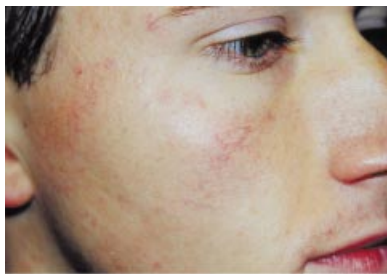Response was graded by the operators as poor = less than 25% clearance, fair = 25–50% clearance, good = 50–75% clearance and excellent = 75–100% clearance. Evaluation of the clinical results was based on comparison of the images of pretreatment photographs (taken with informed consent) with post-treatment appearance of the treated areas.

Results

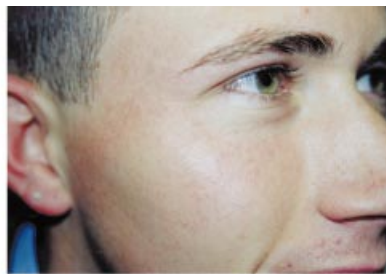The clinical effects of the treatment were easily appreciated; facial telangiectasias and small calibre leg veins showed immediate contraction with disappearance of the vessel margins during treatment. The laser treatments did produce a burning sensation during the application, but this was well tolerated by all the subjects.

All the subjects with facial telangiectasia achieved excellent results with 95–100% clearance (Table 1). All these subjects experienced a few hours of transient erythema and some very mild swelling and crusting that lasted for a few days. No scarring, purpura, textural or permanent pigmentary changes were noted. None of the subjects had to interrupt his/her social life for the procedure (figs 1, 2, 3).

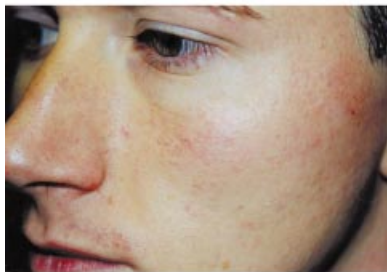In the leg vein group (group 2; Table 2), four subjects had excellent results after one single treatment, seven had good results after two treatments and 15 had good/excellent results after three treatments, two had good results after four treatments and one had excellent results after five sessions (fig. 4). Three patients obtained poor/fair results after two and three sessions. The subjects showed immediate intravascular pigment darkening (greyish or bluish colour) and perivascular erythema at the end of each session. The skin overlying the vessel was usually slightly depressed for a few minutes after the application



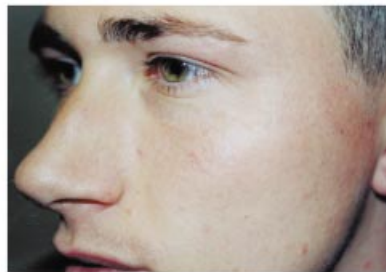a)



b)

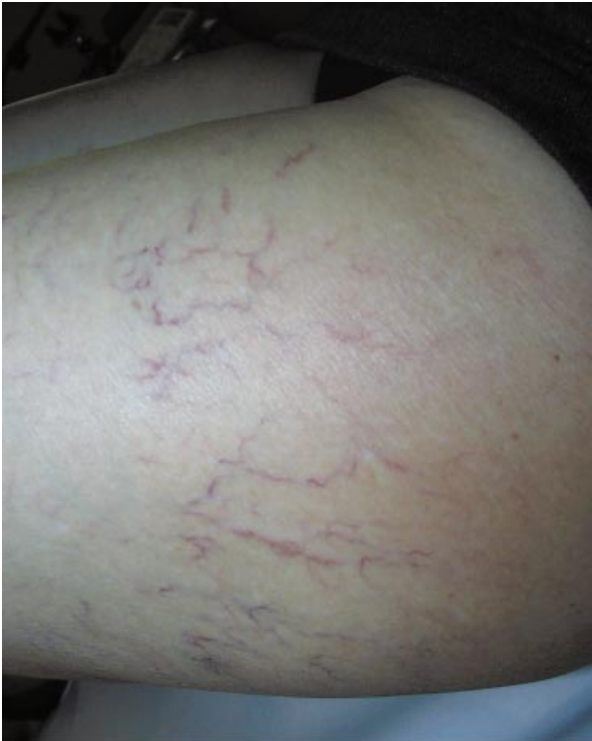

c)

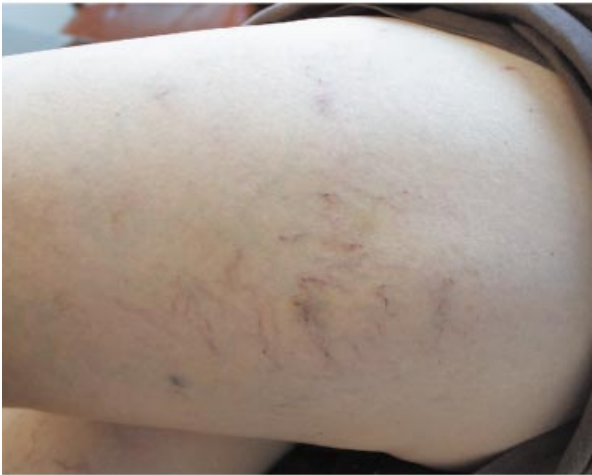


d)

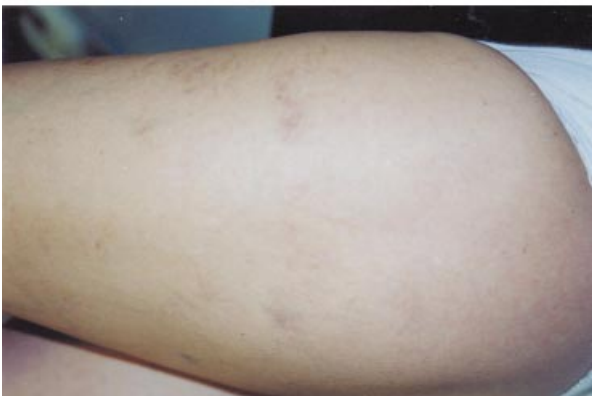
fig. 3 Facial telangiectasias: (a, c) before treatment, and (b, d) 30 days after one treatment session with Nd:YAG 1064 nm laser.



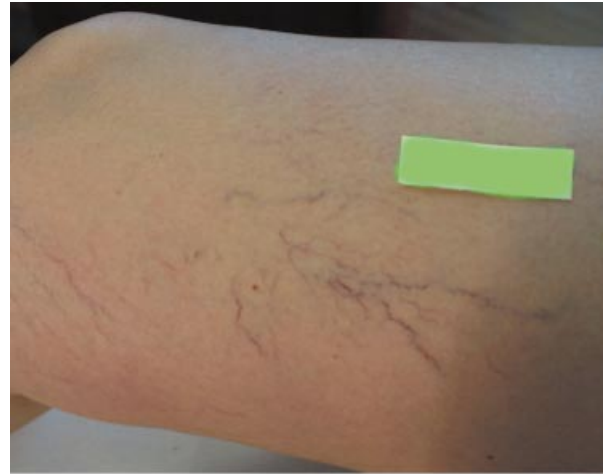
a)



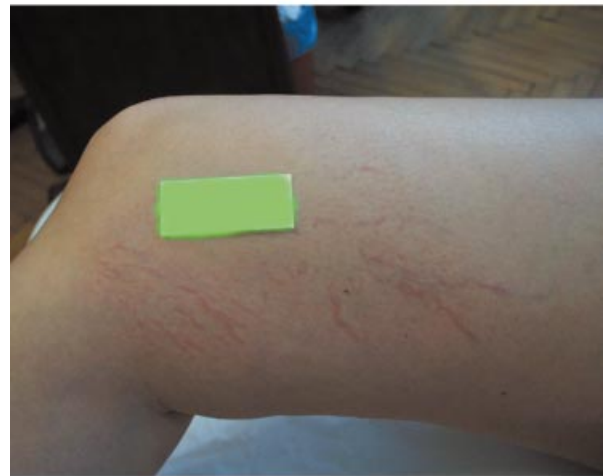b)



c)



a)



b)

fig. 5 (a) Leg telangiectasias before treatment. (b) Intense erythema 20 min after laser treatment.

fig. 4 Leg telangiectasias: (a) before treatment; (b) after 6 months (three treatment sessions); and (c) after 12 months (five treatment sessions).

with subsequent erythema and oedema that lasted for a few hours (fig. 5).

Transitory dotted hypopigmentations of the legs were seen in only two patients.

Discussion

Although sclerotherapy remains the gold standard of treatment in this type of affection, an alternative efficacious treatment is necessary because many subjects are afraid of injections, are allergic to sclerosing agents, or risk various postsclerotherapy complications (postsclerosis pigmentation, telangiectatic matting).^{7,8}

Recently, many laser devices (flashlamp-pumped tunable pulsed dye 585–600 nm laser, long-pulsed frequency doubled Nd:YAG 532 laser)^{9–11} and non-coherent pulsed light sources (515–1200 nm)¹² have been employed for the treatment of ectatic leg vessels, but these studies have given satisfactory results only for red, small calibre (< 1.0 mm) superficial vessels.

Longer wavelengths and long-pulse options (pulsed alexandrite 755 nm laser and 1064 nm Nd:YAG)^{6,13} have recently been proposed for the treatment of larger (up to 3 mm in diameter) and slightly deeper leg telangiectasias in an attempt to produce an epidermal bypass that targets haemoglobin, but does not cause thermal damage to the epidermis. At 1064 nm wavelengths melanin has little influence on the absorption, permitting treatment of darker skinned individuals with minimal risk of dischromia.⁵ In addition, the reduced scatter at 1064 nm allows full penetration into a small superficial vessel as well as into a deeper dermal blood vessels and incomplete absorption by the chromophore itself allows full thickness vessel penetration.

Although 1064 nm wavelength is at the far end of the broad band of haemoglobin absorption, a previous experience with large deoxygenated telangiectasias (0.5–3 mm) had demonstrated that this wavelength, applied at up to 16 ms pulses, could achieve clinical elimination of an ectatic leg vein.⁵

With wavelengths in the near infra-red spectrum epidermal injury is less likely to occur because of the minor interaction with melanin and, according to the theory of selective photothermolysis,¹⁴ the spatial confinement of thermal damage is enhanced when the pulse duration of the laser is less than the thermal relaxation time of the target. For vascular lesions this time varies according to the size of the vessel. A short pulse duration can spatially limit the heat transfer to the vessel, but it may at the same time cause vessel rupture due to rapid vaporization of erythrocytes. Clinically this is manifested as purpura and can evolve into pigmentation very similar to that of postsclerotherapy hyperpigmentation. This phenomenon always occurs with laser pulsing in the range of nanoseconds. The ideal pulse duration should therefore be long enough to inflict damage to the endothelial cells, but not long enough to cause extensive perivascular damage that may determine

scarring. Dierick *et al.*¹⁵ suggested that for small cutaneous telangiectasias a pulse greater than 1 ms may be the most effective. A longer pulse duration achieves slower heating of the vessel allowing sufficient vessel damage to cause coagulation, but avoiding vessel rupture, subsequent purpura and possible hyperpigmentation.

Sadick *et al.*⁶ have recently suggested the efficacy of 1064 nm wavelength in the treatment of leg reticular veins and venulectasias. They believed that this was the first report on the use of a long pulse 1064 nm Nd:YAG laser for leg telangiectasias; all previous reports were based on shorter wavelengths, those more effectively absorbed by haemoglobin.^{1,14,16–18}

Our data demonstrate that the long pulse 1064 nm is effective and safe for treating face telangiectasias, and that vessels cleared with a single treatment. Side-effects were minimal and included crusting lasted 14–21 days without permanent pigmentary changes. In addition, subjects could return to normal life immediately after the treatment. However, there are no significant differences between our results and those obtained previously with shorter wavelength lasers.

Regarding the treatment of leg telangiectasias, our study demonstrated a good/excellent clearance in most patients after one to five sessions, depending on vessel diameter. Small vessels (0.2–0.8 mm) cleared quickly, while larger ones needed more time to disappear. In addition, treatment of larger leg veins was associated with increased discomfort. There were no cases of vessel rupture nor of permanent hyperpigmentation; two subjects manifested dotted hypopigmentation that resolved in 2–3 months.

These preliminary results with long pulsed 1064 nm Nd:YAG laser confirm the wide range of application of this 'friendly' wavelength, indicating that it can be safely and effectively used for hair removal as well as for removal of small to medium disfiguring leg veins and unsightly face capillaries.

References

- West TB, Alster T. Comparison of the long pulsed dye (590–595 nm) and KTP (532 nm) lasers in the treatment of facial and leg telangiectasias. *Dermatol Surg* 1998; **24**: 221–226.
- Silver BE, Livshots YL. Preliminary experience with the KTP/532 nm laser in the treatment of facial telangiectasias. *Cosmet Dermatol* 1996; **9**: 61–64.
- Adrian RM, Tanghetti EA. Long-pulse 532-nm laser treatment of facial telangiectasia. *Dermatol Surg* 1998; **24**: 71–74.
- Angermeier MC. Treatment of facial vascular lesions with intense pulsed light. *J Cutan Laser Ther* 1999; **1**(2): 95–100.
- Weiss RA, Weiss MA. Early clinical results with a multiple synchronized pulse: 1064 nm laser for leg telangiectasias and reticular veins. *Dermatol Surg* 1999; **25**: 399–402.
- Sadick NS, Prieto VG, Shea CR *et al.* Clinical and pathophysiologic correlates of 1064-nm Nd:YAG laser treatment of reticular veins and venulectasias. *Arch Dermatol* 2001; **137**: 613–617.

- 7 Goldman MP, Kaplan RP, Duffy DM. Postsclerotherapy hyperpigmentation: a histologic evaluation. *J Dermatol Surg Oncol* 1987; **13**: 547–550.
- 8 Goldman MP, Sadick NS, Weiss RA. Cutaneous necrosis, telangiectatic matting and hyperpigmentation following sclerotherapy: etiology, prevention and treatment (review). *Dermatol Surg* 1995; **21**: 19–29.
- 9 Hsia J, Lowery JA, Zelikson B. Treatment of leg telangiectasia using a long pulsed dye laser at 595nm. *Lasers Surg Med* 1997; **20**: 1–5.
- 10 Alora MB, Stern RS, Arndt KA, Dover JS. Comparison of the 595 nm long-pulse (1.5 msec) and ultralong-pulse (4 msec) lasers in the treatment of leg veins. *Dermatol Surg* 1999; **25**(6): 445–449.
- 11 Adrian RM. Treatment of leg telangiectasias using a long-pulse frequency doubled Nd:YAG 532-nm. *Dermatol Surg* 1998; **24**: 19–23.
- 12 Gree D. Photothermal removal of telangiectases of the lower extremities with the photoderml. *J Am Acad Dermatol* 1998; **38**: 61–68.
- 13 Kauvar ANB, Lou WW. Pulsed alexandrite laser for the treatment of leg telangiectasia and reticular veins. *Arch Dermatol* 2000; **136**: 1371–1375.
- 14 Anderson RR, Parish JA. Microvasculature can be selectively damaged using dye laser: a basic theory and experimental evidence in the human skin. *Lasers Surg Med* 1981; **1**: 263–276.
- 15 Dierick CC, Casparian JM, Venugopalan V *et al*. Thermal relaxation of port-wine stain vessel probed in vivo: the need for 1–10 ms laser pulsed treatment. *J Invest Dermatol* 1995; **105**: 709–714.
- 16 Goldberg DJ, Meine JG. A comparison of four frequency doubled Nd:Yag (532 nm) laser system for treatment of facial telangiectases. *Dermatol Surg* 1999; **25**: 463–467.
- 17 Massey RA, Bruce EK. Successful treatment of spider leg veins with a high energy, frequency doubled Neodymium:Yag laser (HELP-G). *Dermatol Surg* 1999; **25**: 677–680.
- 18 Tan E, Vinciullo C. Pulsed dye laser treatment of spider telangiectasia. *Australas J Dermatol* 1997; **38**: 22–25.

Visit the EADV website at: www.eadv.org